

ENDOPHTHALMITIS BY Bacillus cereus AFTER PHACOEMULSIFICATION

**Michelle Vanderlei Gantois¹, Matheus de
Aguiar Madeiro², Priscilla de Araujo Andrade³**

Altino Ventura Foundation
47° BRAVS Meeting/ Retina 2023
April 28th to May 1st

PURPOSE

To report the case of a patient with postphacoemulsification endophthalmitis caused by *Bacillus cereus*

CASE REPORT

- Male patient, 58 years old; with low visual acuity in the right eye (OD) 7 days after phacoemulsification with intraocular lens (IOL) implantation; At the first visit, visual acuity 1.0 logMAR; on biomicroscopy of the RE: hyperemic conjunctiva 2+, Descemet's folds 2+, without hypopyon, trophic iris, IOL in situ. At the funduscopy of the OD: visualized only a shadow of the optic disc and retina in the posterior pole, vasculature without alterations in the periphery performed ultrassoud (image 1). He was then submitted to vitreous collection for microbiological analysis/study, posterior vitrectomy + membranectomies + expander gas infusion + vancomycin/ceftazidime/dexamethasone injection. On the 1st postoperative day, there was condensation and vitreous opacification in the posterior pole and inferior retina (image 2). The next day, he was re-approached with a new posterior vitrectomy + silicone oil implant + vancomycin/ceftazidime/amphotericin B injection. After clinical follow-up, there was an improvement in visual acuity to 0.3 logMAR in RE on the 38th day (images 3 and 4)

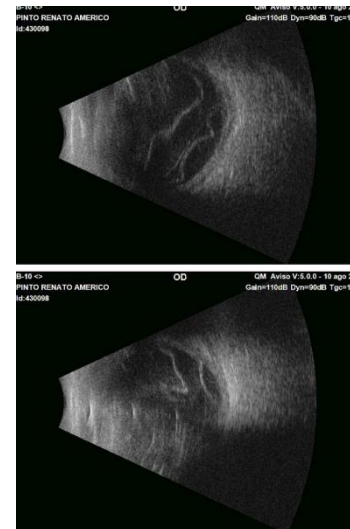


Image 1

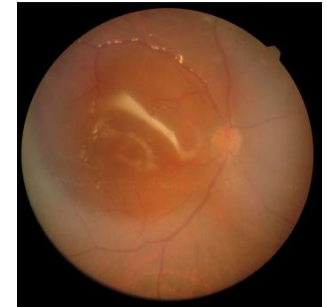

Image 2

DISCUSSION

Endophthalmitis due to *B. cereus* is a rare event with potentially significant consequences. In this report, it was possible to identify an important clinical and surgical improvement, in view of the severity of the infection and that, in most cases, there is irreversible damage. Understanding the intraocular inflammatory signals driven by this pathogen and its products are essential to implement effective therapeutic strategies against this infection.¹

REFERENCE

Mursalin MH, Livingston ET, Callegan MC. The cereus matter of Bacillus endophthalmitis. Exp Eye Res. 2020 Apr;193:107959. doi: 10.1016/j.exer.2020.107959. Epub 2020 Feb 4. PMID: 32032628; PMCID: PMC7113113

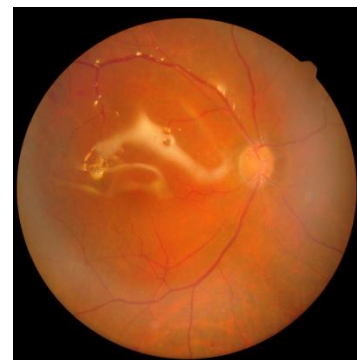

Image 3

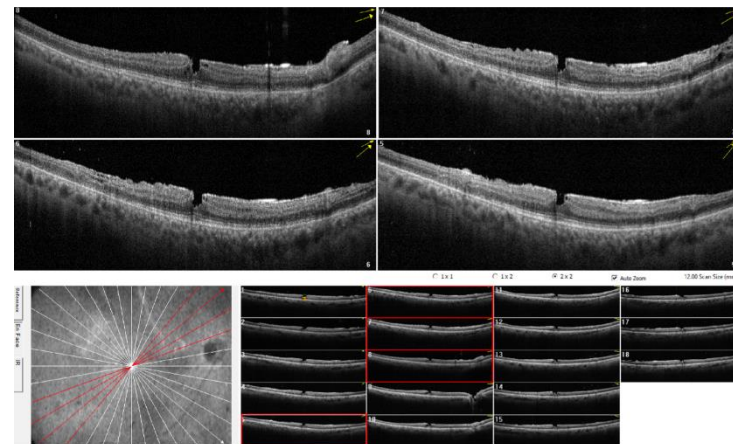


Image 4