

# **INADVERTENT INTRAOCULAR INJECTION OF TATTOO INK: CASE REPORT**

**Marcelo C Ventura Filho<sup>1</sup>, Camila V Ventura<sup>1</sup>, Liana O Ventura<sup>1</sup>**

E-mail: [marceloventurafmd@gmail.com](mailto:marceloventurafmd@gmail.com)

<sup>1</sup>Altino Ventura Foundation

47° BRAVS Meeting/ Retina 2023

April 28<sup>th</sup> to May 1<sup>st</sup>

## PURPOSE

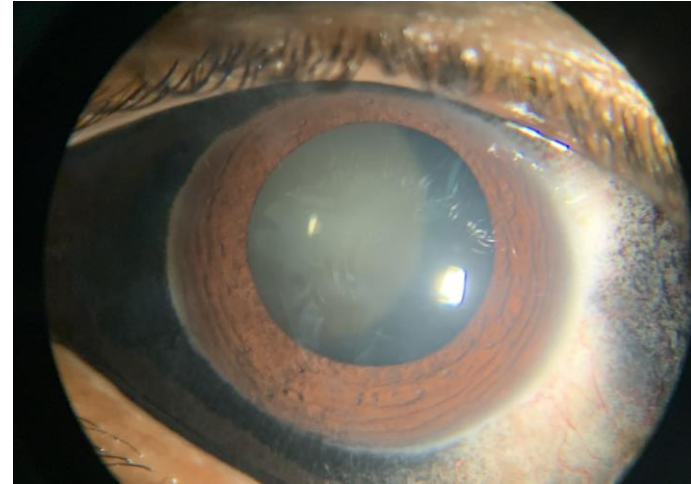
- To report a case of a patient submitted to an inadvertent intravitreal ink injection when trying to tattoo the conjunctiva of the left eye

## METHODS

- Case report

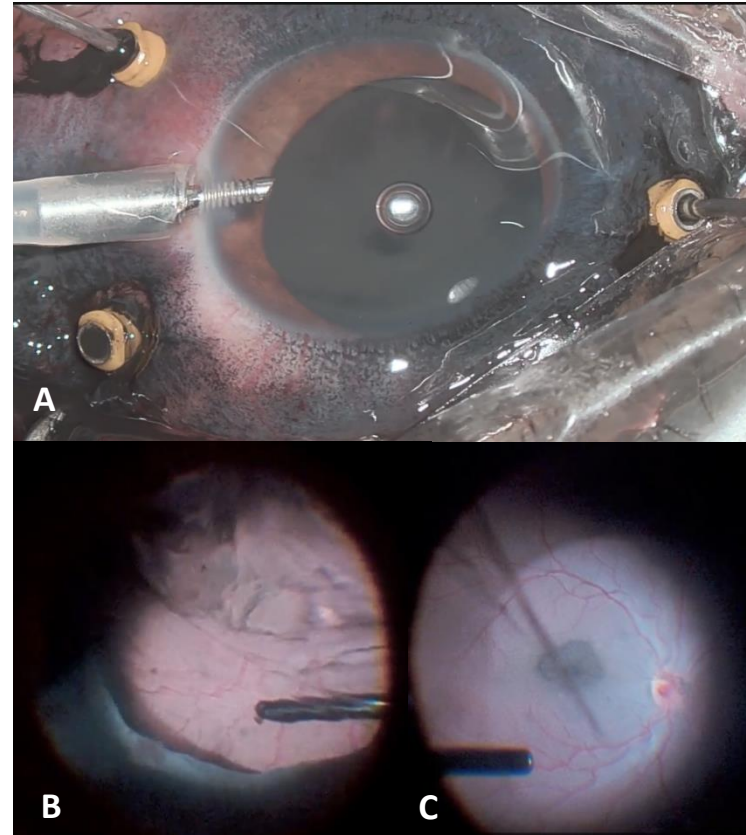
## RESULTS

- 27 Y.O. male
- Referring low visual acuity after tattooing OS



# RESULTS

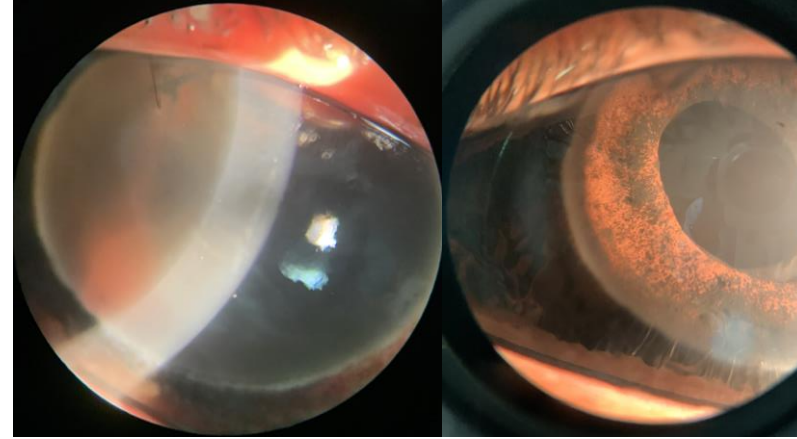
- Inicial assessment
  - Tattooed conjunctiva, transparent cornea, formed anterior chamber and translucent lens
  - BCVA: Hand movement
  - IOP 7mmHg
- Surgical procedure
  - Pars plana vitrectomy, photocoagulation at posterior perforation point, FAX with C3F8
  - Phacoemulsification without IOL implantation after posterior capsule rupture



A- Ink reflux through trocars; B- Impregnated vitreous; C- Thin macular layer impregnation

# RESULTS

- Follow-up
  - Severe granulomatous uveitis (controlled during post op month 1)
  - Secondary glaucoma
  - Attempted hemi-gatt technique during secondary IOL implantation surgery
  - IOP control achieved after glaucoma drainage device implantation



POD #3

POD #24



A- Secondary IOL implantation;  
B- Impregnated trabecular mesh;  
C- Hemi-gatt technique

# CONCLUSION

- This case report highlights a rare topic in the literature that may become more frequent with the growing popularity of conjunctiva and scleral tattoos
  - The surgical difficulty and post op follow-up challenges
  - Severe complications associated, such as uveitis, and glaucoma were present in this case and previously reported in similar cases
  - Long-term visual prognosis and complications are unknown and will only show with time

# REFERENCE

- Tubek K, Berus T, Leszek R. The girl with the eyeball tattoo-what the ophthalmologist may expect? Case report and a review of literature. *Eur J Ophthalmol.* 2019 Sep;29(5):NP1-NP4.
- Cruz NF, Santos KS, Farah ML, Felberg S. Conjunctival Tattoo With Inadvertent Globe Penetration and Associated Complications. *Cornea.* 2017 May;36(5):625-627.
- Haq Z, Pasricha N, Bever G, Seitzman G, Stewart JM. Delayed Acute Granulomatous Anterior Uveitis after Inadvertent Intraocular Injection of Tattoo Ink from a Scleral Tattoo Procedure. *Ocul Immunol Inflamm.* 2021 Jul 4;29(5):1029-1031.