

UNEXPECTED DISCOVERY: EXPLORING THE SIGNIFICANCE OF BERGMEISTER'S PAPILLA



RAQUEL NEZIO DE CARVALHO, MD; CAROLINA M. HANNAS, MD ; ANA LUIZA S. GANDRA, MD ; JULIO ANDRADE, MD ; NEIFFER N. RABELO, MD; MARIA PAULINA V. MIQUILINO, MD ; GIOVANNA V. M. PAIVA, MD; GABRIELA C. BENETI, MD

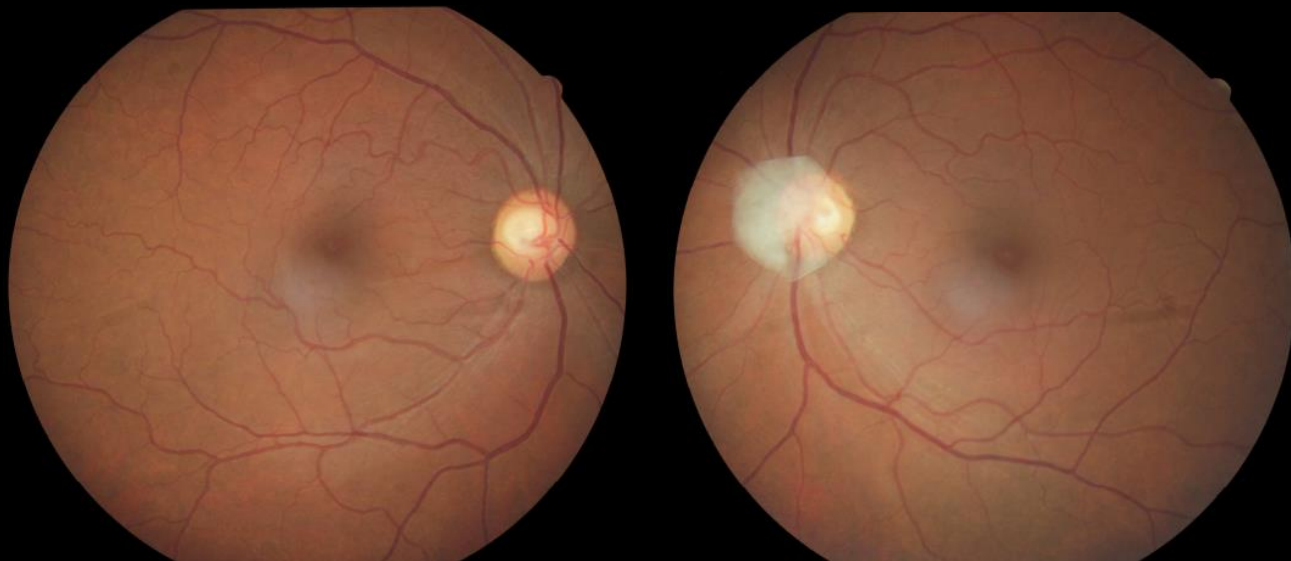
ID: Woman, 44 y old

CC: No complaints, annual propaedeutics

PMH: Hydroxychloroquine - 4.54 mg/kg

POF/PFH: Unremarkable

	OD	OS
SCVA	20/20	20/20
Fundoscopy	Photos	
Slip-Lamp Exam	Normal	Normal



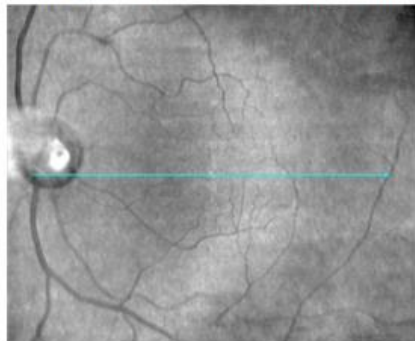
Fundoscopy/Retinography:

OD: Normal

OS: Anomalous ¹whitish overlay atop the optic ²disc

High Definition Images: HD 1 Line 100x

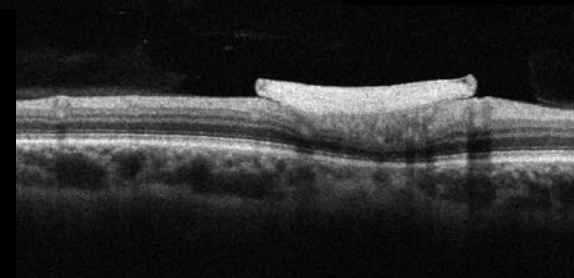
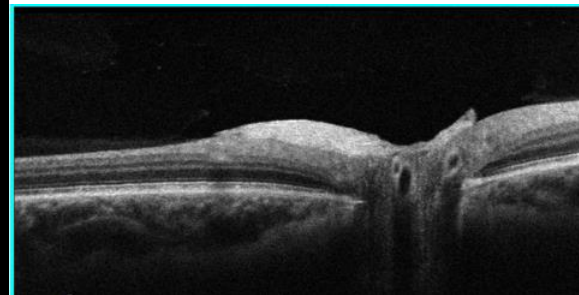
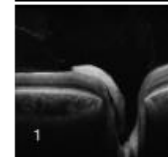
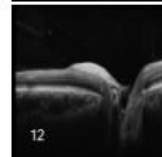
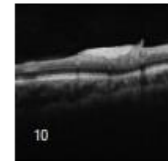
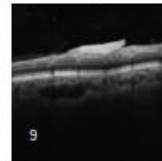
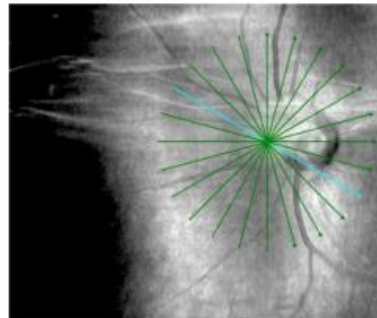
Scan Angle: 0° Spacing: 0 mm



High Definition Images: HD Radial

OD OS

Length: 6 mm



SD-OCT:

OS: A hyperreflective membrane overlying the optic disc with adhesions to the adjacent papillary structure



BERGMEISTER PAPILLA

- Remnant of the fibrous sheath surrounding the **fetal hyaloid artery** during embryological development
- Typically **asymptomatic**
- **Hyperreflective membrane** with adhesions to the adjacent papillary structure

Neovascularization of the fibrosed optic disc (NVD)

- Differential diagnosis
- Complications: Vitreous hemorrhages, tractional retinal detachment and macular hole
- Distinct tomographic features indicative of fibrovascular proliferation and associated pathological changes
- **SD-OCT** facilitates the differentiation between BMP and NVD thereby obviating the need for invasive diagnostic modalities